

## Accessory Head of Flexor Pollicis Longus Muscle

Sharma<sup>1</sup>, M., Chhabra<sup>2</sup>, U., Kaushal<sup>2</sup>, S., Patnaik<sup>3</sup>, V.V.G. and Prashar<sup>2</sup>, R.

<sup>1</sup>Gian Sagar Dental College, Rampur, Banur, Patiala (Punjab), Email: rprashardr1195@rediffmail.com

<sup>2</sup>Govt. Medical College, Patiala (Punjab)

<sup>3</sup>MMIMS, Maulana-Ambala (Haryana)

### Abstract

The superior extremity of man has undergone various modifications during evolution. The flexor pollicis is an important muscle of the hand. A cadaveric dissection study of 60 upper extremities was done to determine the incidence of occurrence, morphology and relations of the accessory head of the flexor pollicis muscle. The accessory head of the flexor pollicis longus was found to be present in 24 (40%) upper extremities. In all cases (except two where they were getting origin from the fascia around the median nerve) it was found to be fused with the other muscles of the flexor pronator group of the forearm. In one case two accessory bellies were present. The tendon of accessory belly was merging with the tendon of flexor pollicis longus in all cases. In a case where two bellies were present in that the tendon of second belly was merging with the tendon of flexor digitorum profundus. The accessory belly was getting nerve supply from median nerve in 8 cases (33.33%) directly and from the anterior interosseous nerve in 16 cases (66.7%). The accessory belly per se may cause entrapment neuropathy of median and anterior interosseous nerve.

**Key Words:** Flexor muscles, Human cadavers, Accessory head, Evolution, Volar incision, Entrapment neuropathy

### Introduction

The superior extremity of man has undergone various modifications during evolution. The flexor pollicis is an important muscle for the function of hand. It is absent in primates such as gorilla and chimpanzee in whom a well developed flexor hallucis longus perform the same function as that of flexor pollicis longus performs in man (*Mangini, 1960*).

The flexor pollicis longus muscle is described as arising chiefly from grooved anterior surface of the radius extending from below its tuberosity to the upper attachment of pronator quadratus muscle and adjacent interosseous membrane. In addition the flexor pollicis longus muscle may have additional origin from the medial border of the coronoid process of the ulna or from the medial epicondyl of the humerus. As the muscle is traced downwards, the origin expands to cover the entire

width of the anterior surface of the radius. A short distance above the wrist the tendon becomes rounded and free of muscle attachment and then passes behind the flexor retinaculum. The flexor pollicis longus inserts on the palmar surface of the base of the distal phalanx of thumb (*William et al., 2000*).

The accessory belly of muscle runs distally and obliquely from medial to lateral side underneath the flexor digitorum superficialis to join the principal flexor pollicis muscle and its tendon (*Hemmady, 1993*).

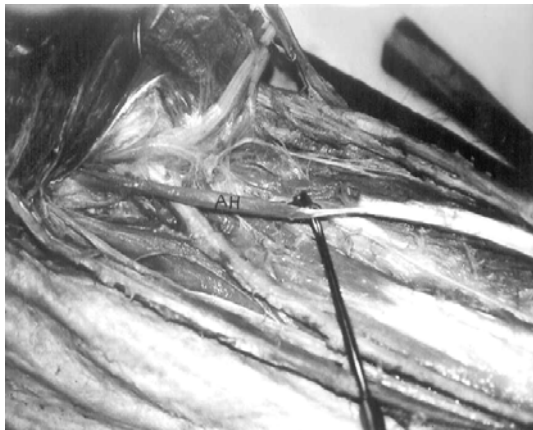The flexor pollicis longus muscle is a comparatively recent acquisition in the evolution of hand. The study of its morphology is interesting from many view points, especially since it has definite clinical significance in injuries and surgical approaches around the elbow joint (*Mangini, 1960*).

The current study is concerned with the frequency of occurrence of accessory head of flexor pollicis longus muscle, its morphology, its relation to the structures of the proximal forearm and the clinical significance thereof.

**Materials and Methods**

For this study, 60 upper limbs of adult human cadavers (56 males and 4 females) were dissected. The dissection was done by using a volar incision extending from the distal arm to the insertion of flexor pollicis longus muscle. The accessory head was brought into view upon reflection of skin, superficial fascia, palmaris longus, flexor carpi radialis and flexor digitorum superficialis muscle. An attempt was made to trace the accessory head to its origin and its relation with other structures of the forearm was studied.

**Results**

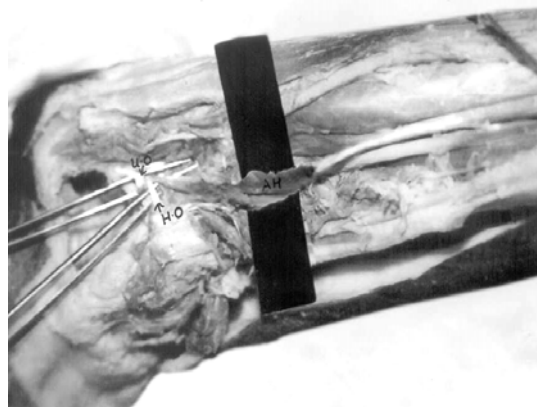

**Figure 1: Accessory Head of Flexor Pollicis Longus**

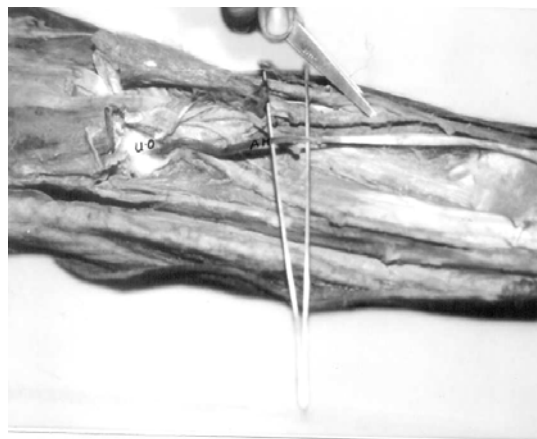
An accessory head of flexor pollicis longus was present in 24 (40%) upper extremities. In 11 cases (10 males and 1 female cadaver) it was bilaterally present and in two cases (both male cadavers) it was present

only on one side. Out of these two cases one belly was lying on right side of one cadaver and in another it was lying on left side. The proximal attachments of accessory head are tabulated below:


Total Number of Extremities Dissected	60	(%)
Accessory Head Present	24	40
Humero-Ulnar Origin	7	29.2
Humeral Origin Only	10	41.7
Ulnar Origin Only	1	4.2
From Under Surface Of Flexor Digitorum Superficialis	4	16.7
From Sheath Around The Median Nerve	2	8.33



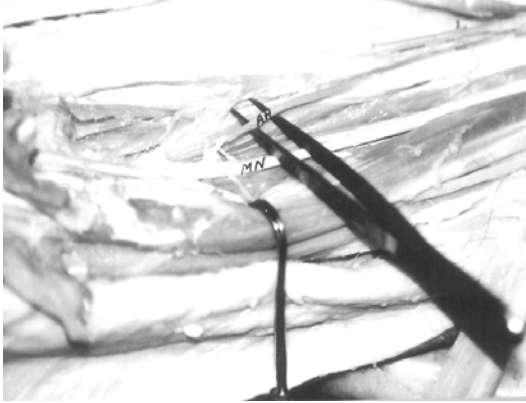
**Figure 2: Humero-ulnar origin**



**Figure 3: Ulnar origin**



**Figure 4: From under surface of flexor digitorum superficialis**

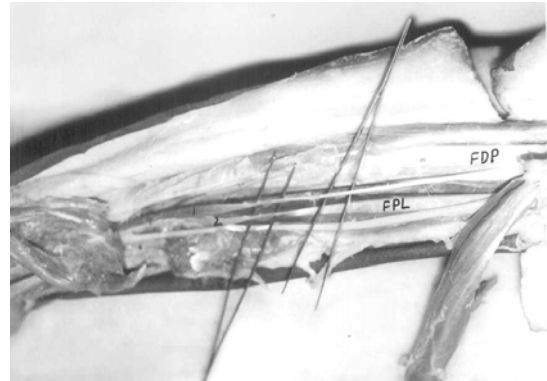


**Figure 5: From sheath around the median nerve**

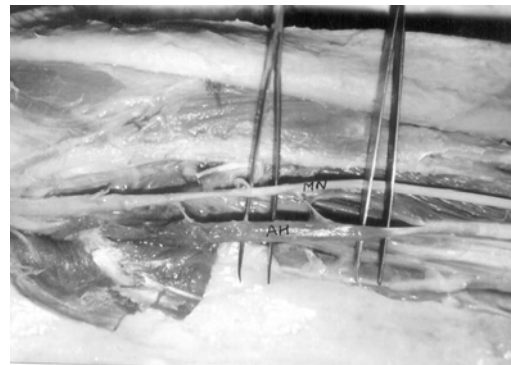In one case (41.2%) two accessory bellies were present. Both of them were gaining origin from the undersurface of flexor digitorum superficialis. In all cases (except two where they were getting origin from the fascia around the median nerve), it was found to be fused with the other muscles of the flexor pronator group of the forearm, probably because phylogenetically they have a common origin from the pronator flexor group of Hamphrey. In some cases they were so intimately blended that separation was extremely laborious. In all cases, the tendon of accessory belly was merging with the tendon of flexor pollicis longus

on superior aspect of medial side except in one case where two bellies were present on left side. In that, tendon of one belly was merging with tendon of flexor pollicis longus on superior aspect of medial side and tendon of second belly was merging with tendon of flexor digitorum profundus about 3 cm above the wrist on lateral side.

The accessory belly was lying between median and anterior interosseous nerve. The nerve supply of accessory belly was from median nerve in 8 (33.33%) cases directly and fibres were entering from superficial surface of the belly and from anterior interosseous nerve in 16 (66.67%) cases entering through deep surface of belly.



**Figure 6: Two accessory bellies**



**Figure 7: Median nerve supplying the belly**

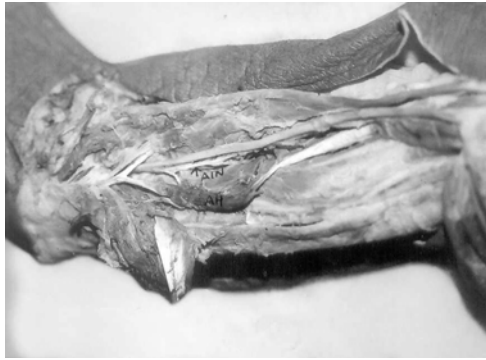

Figure 8: Nerve supply from anterior interosseous nerve

## Discussion

The accessory belly of flexor pollicis longus was seen to be present more frequently (40%) than absent. The morphology and relations of this belly are of great importance from clinical point of view.

The accessory belly per se may cause entrapment neuropathy of the anterior interosseous nerve (Crenshaw, 1992). Also cicatricial contraction of the accessory belly of the flexor pollicis longus muscle (as seen in Volkman's ischaemic contracture or following surgical or non-surgical trauma around the proximal forearm and elbow) may lead to entrapment of the median and anterior interosseous nerves since they are so closely related to this belly. In addition, the median nerve may get entrapped between the humeral origin of the accessory belly and flexor carpi radialis.

The presence of accessory belly has to be borne in mind during anterior approaches to the proximal radius and the elbow joint as also during a decompressive fasciotomy for compartment syndrome of the forearm.

Kaplan (1942) has described a case of a long standing flexion contracture of the interphalangeal joint of the thumb following a fracture dislocation of the elbow which was later found to be due to the cicatricial contraction of the accessory belly of the flexor pollicis longus and had to be subsequently elongated to correct the deformity. Hence in a flexion deformity of the thumb involvement of the accessory belly has to be kept in mind.

## References

- Crenshaw, A.H. 1992. *Campbell's operative orthopaedics*. 8<sup>th</sup> edition. C.V. Mosby and Company, Missourie.
- Hemmady, M.V. 1993. Subramanya, A.V. and Mehter, I.M. Occasional head a flexor pollicis longus muscle: A study of its morphology and clinical significance. *J. Postgrad. Med.*, **39(1)**:14-16.
- Kaplan, E.B. 1942. Correction of a disabling contractive of the thumb. *Bull. Hosp. Joint. Dis.*, **3**: 51-54.
- Mangini, U. 1960. Flexor pollicis longus muscle-its morphology and clinical significance. *The Journal of Bone and Joint Surgery*, **42A(3)**: 467-470.
- William, P.L., Bannister, L.H., Berry, M.M. et al. 2000. Musculoskeletal system. In: *Gray's Anatomy*. 38<sup>th</sup> edition Churchill Livingstone, New York.