

## **Hypoplasia of a Permanent Incisor Produced by Primary Incisor Intrusion: A Case Report**

**Verma, Leena**

Sr. Asst. Professor, Dr. H.S. Judge Institute of Dental College, Punjab University, Chandigarh

### **Abstract**

Orofacial trauma is common in athletic children and is a serious orodental and general health problem that may have medical, esthetic and psychological consequences for children and their parents. When the root of the primary tooth is close to the unerupted permanent tooth, primary tooth trauma may result in developmental disturbances in the permanent tooth. In the present study a case report of an unusual case in which injury to the primary dentition resulted in developmental disturbances in the crown and the non eruption of the permanent tooth is presented. Localized malformation of the crown of the permanent maxillary right central incisor and enamel hypoplasia were treated with a light-cured composite resin restoration. The unerupted permanent left central incisor was removed surgically. The study also discusses the management after extraction with removable partial denture.

**Keywords: Orofacial trauma Maxillary Enamel Hypoplasia**

### **Introduction**

Injuries to primary dentition are among the most common traumas that occur in the maxillofacial region; 30%–40% of all children injure at least one of their primary teeth (Flores *et al*, 2007). Consequences of such trauma include colour changes, pulp necrosis, obliteration of the pulp canal, gingival retraction, tooth displacement, pathological root resorption, alterations in the process of normal root resorption and premature loss of the primary tooth (Borum & Andreasen, 1998). Sequelae in the permanent dentition after trauma to primary dentition are usually related to intrusive injury; either the coronal or root region, or the entire permanent tooth germ may be affected (Gondim & Moreira Neto, 2005). An intrusive injury occurs when the impact of an axial force displaces the tooth within the socket. Between 18% and 69% of intrusive injuries to the primary dentition cause anomalous development of the

permanent teeth (Holan *et al*, 2002). Such alterations in dental pathology can include white or yellow brown discoloration, or circular enamel hypoplasia; crown dilaceration; root duplication; vestibular or lateral root angulation or dilaceration; partial or complete arrest of root formation; sequestration of the permanent tooth germ; and disturbed eruption (Flores, 2002) Depending on the age of the child at the time of injury and the direction and severity of the trauma, force transmitted from the affected primary tooth may result in similar consequences to the underlying unerupted permanent tooth. In the following report, we present the case of a 10 year old boy in which there is uneruption and localized crown malformation of the right permanent central incisor and enamel hypoplasia in the permanent left central incisor which was caused by trauma to its preceding primary tooth while playing at play

school. This case report also discusses the management in such case .

### Case Report

A 10-year-old boy came to Dr Harvansh Singh Judge Institute Of Dental Sciences ,Panjab Univeresity, Chandigarh with a chief complaint of the noneruption of right central incisor. His past dental history revealed that at 2 years of age he had injured his primary maxillary central incisors during play at play school. After the injury, he had emergency treatment that involved suturing the lip and antibiotics at a hospital, but no professional dental treatment. Other medical records revealed that he had no general pathologic condition. Clinical examination revealed that the patient had an unerupted permanent maxillary right central incisor, crown malformation and enamel hypoplasia of the permanent maxillary left central incisor. (Fig. 1).

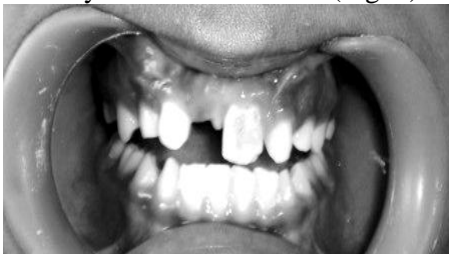

Figure 1: Preoperative photograph of the patient showing unerupted right maxillary central incisor and hypoplastic left maxillary central incisor

Radiographic examination showed unerupted permanent right central incisor. Additional brown lines and yellow discoloration were observed on the left central incisor. Now since the unerupted permanent maxillary left central incisor was malformed and was deeply placed in the bone so it was decided to extract the teeth. The treatment plan developed included flap raising in the area of

noneruption of permanent right central incisor .Two vertical shaped incisions were given in the gingiva and the flap was raised with the help of periosteal elevators. (Figure 2) On raising the flap the unerupted right central incisor was seen and extracted.

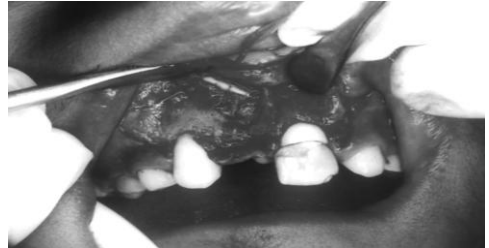


Figure 2: Figure showing exposed periosteal flap with unerupted right central incisor

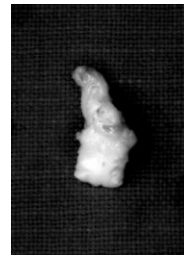

Figure 3: Figure showing extraction of the unerupted central right incisor

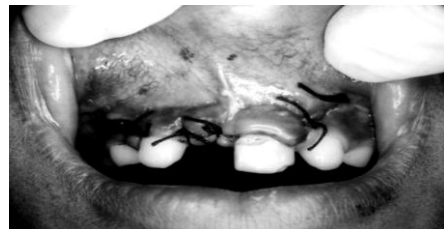

Figure 4: Figure showing sutures placed

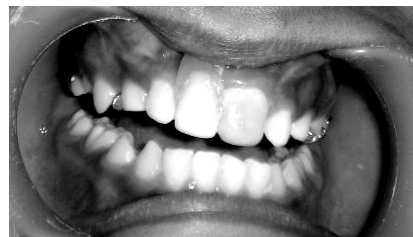

Figure 5: Figure showing removable partial prosthesis placed with respect to maxillary right central incisor

(Figure 3) The sutures were placed. (Figure 4) Patient was given instructions to improve oral hygiene. In maxillary left central incisor removal of the hypoplastic enamel and restoration of the region was done with composite restoration. No problems occurred during the bonding procedure, and occlusal adjustment was done. Because of the positive vitality test, endodontic treatment was not recommended. After the restoration, a periapical radiograph was taken, and the patient was followed up every 3 months. After 2 months the removal partial denture was given in maxillary right central incisor as the permanent canines of the patient were not erupted. (Figure 5).

#### **Discussion:**

An injury to a young child's teeth can be physically and emotionally traumatic. The dentist must take time to carefully examine and analyze not only the damage itself, but also the possibilities of sequelae to the permanent tooth germ and the overall health of the child. For this reason, treatment of trauma in primary dentition must include long-term follow-up of sequelae in the permanent dentition (Cunha *et al*, 2001). The type of sequelae noted in permanent dentition can be explained in part by the age at which the trauma to the primary dentition occurred. Because the majority of traumatic injuries to primary teeth occur when children are between 1 and 3 years of age, developmental disturbances involving the crown of the permanent teeth are reported more frequently than developmental disturbances in the roots and in the eruption of permanent teeth (von Arx, 1993). In the case reported here, developmental disturbances were observed in the crown of left maxillary central

incisor and the non eruption of right maxillary central incisor. Formation of the permanent upper central incisor germ takes place at 20 weeks of gestation, and calcification begins when the child is 3 to 4 months of age. Depending on the severity of intrusion, intruded primary teeth can invade the follicle of the permanent germ and destroy the enamel matrix. Because ameloblasts are irreplaceable and no further cell division occurs after the completed formation of the enamel, trauma will likely arrest localized development of the crown (Turgut *et al*, 2006). In the case reported here, the intrusive orofacial trauma to the primary left incisor that occurred when the patient was 19 months of age likely disturbed the crown formation and enamel matrix of the underlying permanent tooth, and caused changes in its colour and shape. The literature, 17–19 contains a number of descriptions of the relationship between primary tooth trauma and permanent tooth hypoplasia (Bassiouny *et al*, 2003, Kirchner & Jacobs, 2006). White discoloration is caused by the accelerated mineral deposition that results from trauma during the maturation stage of enamel development, whereas yellow-brown discoloration is caused by the incorporation of hemoglobin products from bleeding in the periapical area and enamel hypoplasia is caused by the destruction of ameloblasts in the active enamel epithelium. This trauma also caused the noneruption of permanent right central incisor. This noneruption of teeth is caused by the trauma to primary incisors which led to malformation of the crown and noneruption of the tooth. In a case similar to the one reported here, Katz-Sagi and others found crown malformation in

unerupted maxillary central incisor after trauma to the associated primary tooth (Katz-Sagi et al, 2004).

## Conclusions

The case we report here stresses the importance of traumatic injuries to primary dentition because of their effects on the permanent tooth germ. The dentist must take time to carefully examine and analyze not only the damage itself, but also the possibilities of sequelae to the permanent tooth.

## References

- Bassiouny, M.A., Giannini, P., Deem, L. 2003. Permanent incisors traumatized through predecessors: sequelae and possible management. *J. Clin. Pediatr. Dent.*, **27(3)**: 223–8
- Borum, M.K., Andreasen, J.O. 1998. Sequelae of trauma to primary maxillary incisors. I. Complications in the primary dentition. *Endod. Dent. Traumatol.*, **14(1)**: 31–44.
- Cunha, R.F., Pugliesi, D.M., de Mello Vieira, A.E. 2001. Oral trauma in Brazilian patients aged 0–3 years. *Dent. Traumatol.*, **17(5)**: 210–2.
- Flores, M.T. 2002. Traumatic injuries in the primary dentition. *Dent. Traumatol.*, **18(6)**: 287–98.
- Flores, M.T., Holan, G., Borum, M., Andreasen, J.O. 2007. Injuries to the primary dentition. In: Andreasen, J.O., Andreasen, F.M., Andersson, L., editors. *Textbook and color atlas of traumatic injuries to the teeth*. 4th ed. Copenhagen: Munksgaard; p. 516–41.
- Gondim, J.O., Moreira, Neto. J.J. 2005. Evaluation of intruded primary incisors. *Dent. Traumatol.*, **21(3)**: 131–3.
- Holan, G., Ram, D., Fuks, A.B. 2002. The diagnostic value of lateral extraoral radiography for intruded maxillary primary incisors. *Pediatr. Dent.*, **24(1)**: 38–42.
- Katz-Sagi, H., Moskovitz, M., Moshonov, J., Holan, G. 2004. Pulp canal obliteration in an unerupted permanent incisor following trauma to its primary predecessor: a case report. *Dent. Traumatol.*, **20(3)**: 181–3.
- Sennhenn-Kirchner, S., Jacobs, H.G. 2006. Traumatic injuries to the primary dentition and effects on the permanent successors — a clinical follow-up study. *Dent. Traumatol.*, **22(5)**: 237–41.
- Turgut, M.D., Tekçiçek, M., Canoglu, H. 2006. An unusual developmental disturbance of an unerupted permanent incisor due to trauma to its predecessor — a case report. *Dent. Traumatol.*, **22(5)**: 283–6.
- Von Arx, T. 1993. Developmental disturbances of permanent teeth following trauma to the primary dentition. *Aust. Dent. J.*, **38(1)**: 1–10.

